

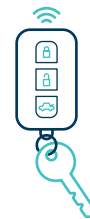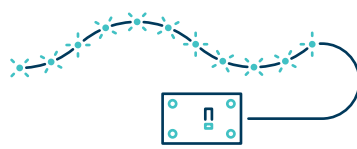

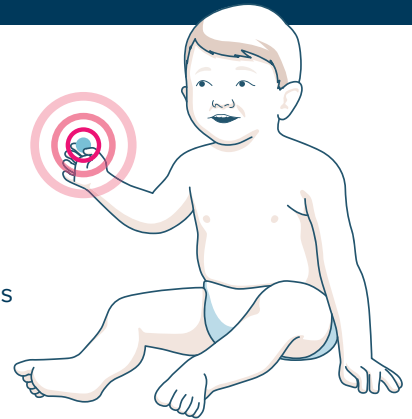


# Button Battery Ingestion in Childhood

*This guide provides a summary of the first European clinical paper on the diagnosis, management, and prevention of button battery ingestion in childhood from the European Society for Paediatric Gastroenterology, Hepatology and Nutrition (ESPGHAN) Button Battery (BB) Task Force*

**Button battery ingestions (BBI) pose a significant health risk for the paediatric population, with an increasing number of cases worldwide, mainly due to the wide abundance of button batteries (BB) in consumer electronics.<sup>1,2</sup>**

According to recent data there has been a seven-fold increase in the relative risk of severe morbidity due to BBI in the last two decades.<sup>3</sup> Of all children worldwide presenting with foreign body ingestion, the percentage of children with battery ingestion is estimated to be as high as 7–25% (approximately).<sup>4–7</sup> Most battery ingestions occur in children < 6 years of age with a peak at 1 year of age, which is also when the highest risk of complications occurs.<sup>1,8</sup>



*Button Batteries can be found in electronic devices, such as remote controls, calculators, LED lights, watches and key fobs*

## Pathophysiology and complications

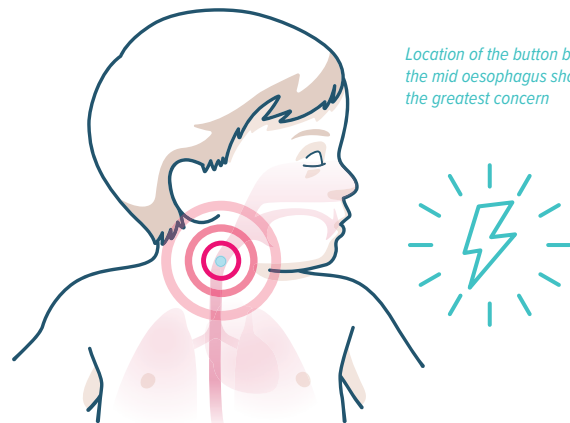
While local pressure necrosis, corrosive damage from leakage of battery content, heavy metal toxicity and electric injury all seem to play a role,<sup>8</sup> electrolysis seems to be the most significant mechanism for damage caused by BBI.<sup>9–11</sup>

Batteries in the oesophagus typically pose the highest risk of complications, especially in children <6 years of age and in batteries >20 mm in diameter. Voltage and duration of the impaction are associated with more rapid and severe injury. Injury to both the anterior and/or posterior wall in the oesophagus can lead to significant complications, while location in the mid oesophagus should alert the greatest concern for aorto-oesophageal fistulae, potentially causing significant bleeding.<sup>12</sup> Fistulisation of both the oesophageal wall and surrounding tissues can lead to several life-threatening complications and death.<sup>8</sup>

Mucosal damage can occur within 2 hours after BB lodgement, even if development of complications typically takes longer. Perforations are usually diagnosed within 2 days (rarely in the first 12 hours), but fistulas can present up to 4 weeks post-removal.

Other complications such as oesophageal strictures, spondylodiscitis or recurrent laryngeal nerve injury may take weeks/months to develop.<sup>1</sup>

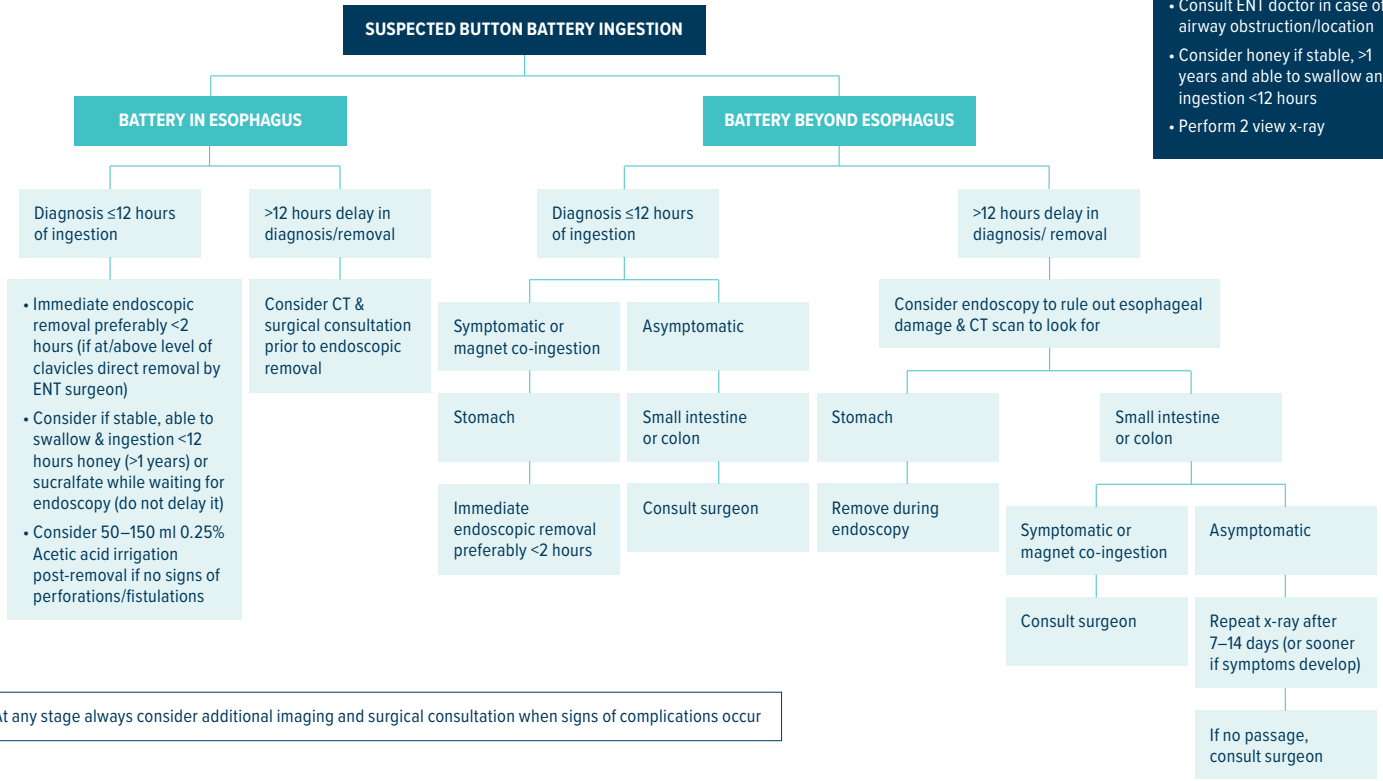
After the oesophagus, BB usually pass the remaining gastrointestinal tract successfully. Only 7% and 1.3% of overall complications occur in the stomach and small bowel respectively as electrolysis does not occur.<sup>8</sup>



*Location of the button battery in the mid oesophagus should alert the greatest concern*

# Diagnosis and management

- FIRST STEPS**
- Check vital signs & manage if abnormal
  - Consult ENT doctor in case of airway obstruction/location
  - Consider honey if stable, >1 years and able to swallow and ingestion <12 hours
  - Perform 2 view x-ray



## Clinical presentation

Early recognition of BBI is critical due to the extremely narrow 2-hour time window for removal of batteries impacted in the oesophagus. Most complications occur after unwitnessed ingestions, as symptoms are variable and nonspecific, leading to delayed diagnosis.<sup>13</sup> Therefore, including battery ingestion in the diagnosis of unexplained symptoms is paramount to avoid delaying the diagnosis and increasing the risk of severe complications and death.



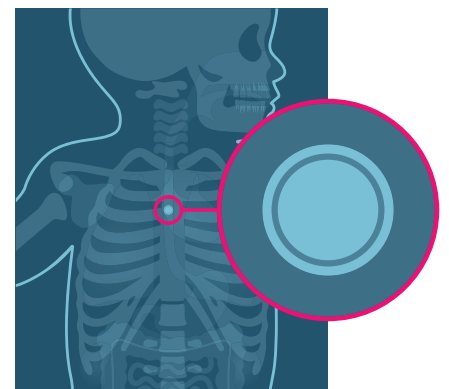
Most witnessed ingestions present with acute gastrointestinal or respiratory symptoms such as vomiting, drooling, dysphagia, odynophagia, irritability, coughing, stridor and shortness of breath. Most unwitnessed ingestions present with hematemesis or hemoptysis, melena, abdominal pain, weight loss, chest pain, cough, stridor, hoarseness, and fever.<sup>2, 14–15</sup>

## Imaging

Following suspected battery ingestion, perform two-view (anterior-posterior and lateral) X-ray of the entire neck, chest and abdomen to diagnose BBI and localise the battery. Close inspection of the image is necessary to identify a double ring or halo sign, which can distinguish a battery from a coin, and to determine the position of the negative pole. N.B. in slimmer batteries the ring or halo may not be seen.

Contrast studies with CT scanning (or MRI scanning **after** battery removal) are necessary to identify complications. If patients have severe mucosal injury or severe symptoms (at presentation or later on) indicative of complications (such as bleeding), it is advised to perform a (serial) CT-scan of the chest and neck **before** the removal, as moving the battery might lead to acute perforation or haemorrhage through a fistula.

In delayed diagnosis of an oesophageal impaction (first confirmation of the BBI on x-ray >12 hours after ingestion or time point of removal >12 hours after ingestion), regardless of symptoms, (serial) CT-scans of the chest and neck should be considered because the BB may have been lodged in the oesophagus previously.



Close inspection of the X-ray image is necessary to identify a double ring or halo sign, which can distinguish a battery from a coin

## Endoscopy and surgery

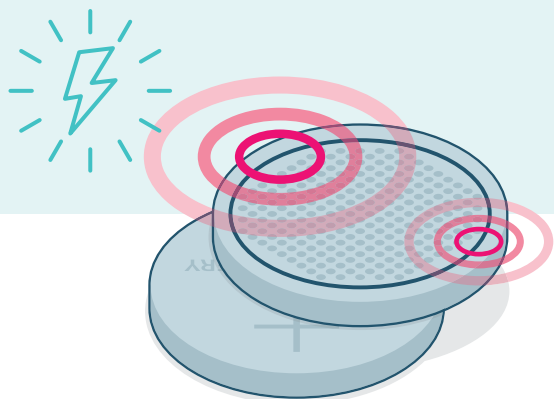
### Oesophageal and airway impaction

In cases where further imaging (CT-scan) has been performed prior to BB removal, a joint approach with (cardiothoracic) surgeons and a cardiac catheter lab may be necessary. Endoscopic removal of the foreign body in the cardiac catheterisation laboratory operation room with fluoroscopic guidance and arteriogram of the aorta allows direct visualisation of the BB and its proximity to the aorta.

When the battery is located in the oesophagus immediate endoscopic removal is necessary, if possible within 2 hours of ingestion, and should not be delayed even if the patient has eaten. This procedure should be performed under general anaesthesia, after intubation of the patient.

During endoscopy the mucosa should be inspected for extent, depth and location of the injury and the direction of the negative pole (side without the “+” sign and without the imprint) should be determined, as this is commonly the most damaged site. In case of significant mucosal damage, a nasogastric tube should be carefully placed endoscopically to maintain patency of the lumen and the patient should not receive any food by mouth until it is certain that no perforation or other complications have occurred.

If the ingested battery is located in the airway or in the gastrointestinal tract at or above the clavicles, an Ear, Nose and Throat (ENT) doctor should be consulted for removal by rigid endoscopy.

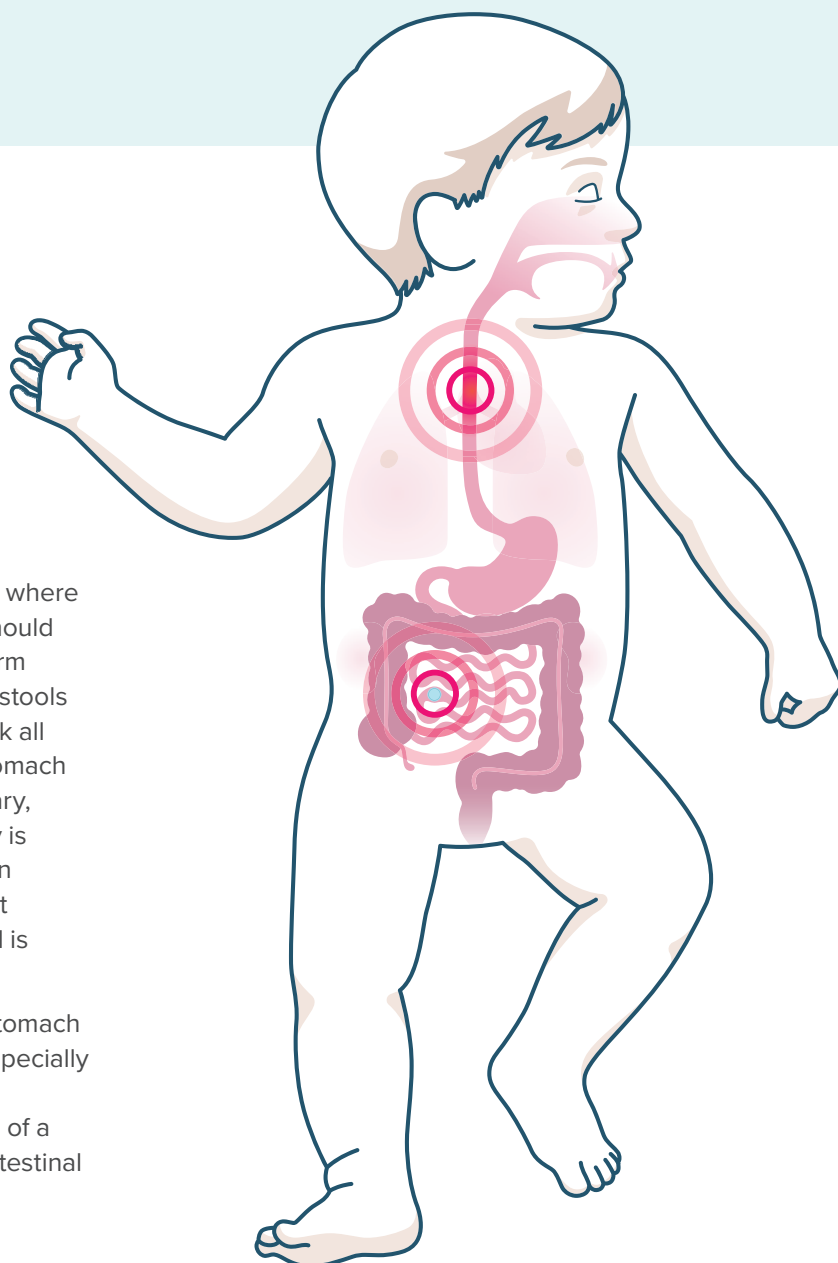


*During endoscopy the direction of the negative pole (side without the “+” sign and without the imprint) should be determined, as this is commonly the most damaged site*

### Location beyond the oesophagus

In order to prevent unnecessary endoscopies, cases where the BB has entered the stomach or small intestine should be followed up after 7–14 days with an X-ray to confirm passage, unless the battery has been noticed in the stools by the parents (parents should be instructed to check all stools). Only if the battery still has not passed the stomach within this timeframe is endoscopic removal necessary, as by then the chance that it will pass spontaneously is expected to be minimal. In case a battery is lodged in the small intestine and causes symptoms or does not pass spontaneously, surgical evaluation and removal is necessary.

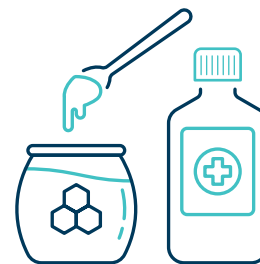It should be noted that the presence of a BB in the stomach or beyond does not exclude oesophageal injury,<sup>16</sup> especially in unwitnessed ingestions when the total time of BB exposure is unknown. Furthermore, the co-ingestion of a magnet may lead to entrapment in the stomach or intestinal wall with the battery and magnet causing necrosis.



*The presence of a button battery in the stomach or beyond does not exclude oesophageal injury*

## pH neutralisation strategies to mitigate injury progression after ingestion

Honey and sucralfate can be considered in ingestions  $\leq 12$  hours while waiting for endoscopic removal but should never delay it. This is thought to limit electrolysis, but also neutralise generated hydroxide as both honey and sucralfate are weak acids. The advised dose for both honey and sucralfate is 10 mL (2 teaspoons) every 10 minutes with a maximum of 6 doses of honey and 3 doses of sucralfate respectively. One should be cautious in case of a delayed diagnosis, clinical suspicion of perforation, mediastinitis, sepsis, swallowing difficulties, allergies to honey or sucralfate and in children  $<1$  year of age due to the small risk for infant botulism with honey intake.<sup>16</sup>



Another mitigation strategy is neutralisation of accumulated tissue hydroxide through acetic acid irrigation immediately following battery removal. This can be done with 50–150 ml 0.25% sterile acetic acid and should only be considered if signs of perforation are absent.

Anaesthetists in every centre should be aware of these pre-endoscopic removal strategies and get involved in the formulation of agreed protocols to avoid unnecessary delays in procedures. The entire specialty needs to be aware of the supporting data on general perioperative considerations for management and potential complications of BBI.

## Post removal evaluation and management and follow-up

All patients with mucosal injury after battery removal should be admitted to the hospital and monitored closely. In these patients a second look within 2–4 days after removal may be considered to ascertain prognostic information. A clear liquid diet may be started if there are no signs of perforation on the oesophagogram, which can be performed 1–2 days after removal.

When a clear liquid diet is tolerated, the diet can progress to soft foods. Broad spectrum antibiotics to prevent mediastinitis should be considered in patients with severe injury, perforation and/or fever.

Long-term follow-up after removal depends on the presence and extent of oesophageal injury. In case of injury, contrast oesophagograms and/or repeat endoscopies are necessary to detect stricture formation, which can occur weeks after the incident. Early dilatation of a stricture will lead to better swallowing function; however, one should wait 4 weeks post-ingestion for the tissue to be healed. Use of acid blockade to minimise the impact of acid reflux on the oesophageal injury seems well justified in cases of mucosal injury.



A clear liquid diet (e.g. gelatin, water, popsicles, clear soup etc.) may be started if there are no signs of perforation on the oesophagogram

### REFERENCES

- Litovitz T, Whitaker N, Clark L, *et al.* Emerging battery-ingestion hazard: clinical implications. *Pediatrics* 2010;125:1168–77.
- Jatana K, Litovitz T, Reilly J, *et al.* Pediatric button battery injuries: 2013 task force update. *Int J Pediatr Otorhinolaryngol* 2013;77:1392–1399.
- Eliason M, Ricca R, Gallaghe T. Button battery ingestion in children. *Curr Opin Otolaryngol Head Neck Surg* 2017;25:520–526.
- Ibrahim A, Andijani A, Abdulshakour M, *et al.* What Do Saudi Children Ingest?: A 10-Year Retrospective Analysis of Ingested Foreign bodies from a Tertiary Care Center. *Pediatr Emerg Care* 2019;71:443–448.
- Khorana J, Tantivit Y, Phiuphong C, *et al.* Foreign body ingestion in pediatrics: Distribution, Management and Complications. *Medicina (Kaunas)* 2019;14:55.
- Diaconescu S, Gimiga N, Sarbu I, *et al.* Foreign bodies ingestion in children: experience of 61 cases in a pediatric gastroenterology unit from Romania. *Gastroenterol Res Pract* 2016; 2016:1982567. Epub 2016 Feb 1.
- Kramer RE, Lerner DG, Lin T, *et al.* North American Society for Pediatric Gastroenterology, Hepatology, and Nutrition Endoscopy Committee. Management of ingested foreign bodies in children: a clinical report of the NASPGHAN Endoscopy Committee. *J Pediatr Gastroenterol Nutr* 2015;60:562–574.
- Varga Á, Kovács T, Saxena AK1. Analysis of complications after button battery ingestion in children. *Pediatr Emerg Care* 2018;34:443–6.
- Jatana K, Rhoades K, Milkovich *et al.* Basic mechanism of button battery ingestion injuries and novel mitigation strategies after diagnosis and removal. *Laryngoscope* 2017;127:1276–82.
- Yoshikawa T, Asai S, Takekawa Y. Experimental investigation of battery-induced esophageal burn injury in rabbits. *Crit Care Med* 1997;25:2039–44.
- Tanaka J, Yamashita M, Yamashita M, *et al.* Esophageal electrochemical burns due to button type lithium batteries in dogs. *Vet Hum Toxicol* 1998;40:193–196.
- Tan A, Wolfram S, Birmingham M, *et al.* Neck pain and stiffness in a toddler with history of button battery ingestion. *J Emerg Med* 2011;41:157–160.
- Litovitz T, Whitaker N, Clark L. Preventing battery ingestions: an analysis of 8648 cases. *Pediatrics* 2010;1178–1183.
- Krom H, Visser M, Hulst J *et al.* Serious complications after button battery ingestion in children. *Eur J Pediatr* 2018;177:1063–70.
- Buttazzoni E, Gregori D, Paoli B, *et al.* Symptoms associated with button batteries injuries in children: an epidemiological review. *Int J Pediatr Otorhinolaryngol* 2015;79:2200–7.
- National Capital Poison Center. Button battery ingestion triage and treatment guideline. <https://www.poisson.org/battery/guideline>. [Accessed: 23 November 2019].

Full references for the advice within this guide can be found within the following paper, which this guide is based upon: de Ridder L, *et al.* Diagnosis, Management, and Prevention of Button Battery Ingestion in Childhood: A European Society for Paediatric Gastroenterology Hepatology and Nutrition Position Paper. *J Pediatr Gastroenterol Nutr* 2021;73(1):129–136. Available at: [https://journals.lww.com/jpgn/Fulltext/2021/07000/Diagnosis,\\_Management,\\_and\\_Prevention\\_of\\_Button.27.aspx](https://journals.lww.com/jpgn/Fulltext/2021/07000/Diagnosis,_Management,_and_Prevention_of_Button.27.aspx)

ESPGHAN is not responsible for the practices of physicians and provides guidelines and position papers as indicators of best practice only. Diagnosis and treatment are at the discretion of physicians. This advice guide is produced and published by the European Society for Paediatric Gastroenterology, Hepatology and Nutrition (ESPGHAN) and authored by members of the society's Gastroenterology Committee.